



PATIENT

Morrison Sgrosso

PRESENTING CLINICAL SIGNS

History: Gallop rhythm heard at annual. T4 normal. Rest WNL. BP: 148, 150, 150mmHg.

SPECIES

Feline

ELECTROCARDIOGRAPHIC FINDINGS *Note: Single lead ECGs are evaluated as a rhythm strip. Morphology/MEA cannot be definitively commented on.

A single lead ECG is available; 25mm/s, 20mm/mV. The underlying rhythm is sinus in origin with an average heart rate of 188bpm. The rhythm is sinus in origin, with a p for every QRS complex and vice versa. P and QRS morphologies are positive. Isolated VPCs throughout; primarily singles and monomorphic. Occasional tight couplets observed. No supraventricular premature beats, pauses or other dysrhythmias observed. ECG diagnosis: Normal sinus rhythm with single and couplet VPCs.

BREED

DSH

SEX

Male Neutered

ECHOCARDIOGRAM FINDINGS

2D, m-mode, color flow and Doppler imaging is available.

Left ventricle: The LV diameter is borderline increased with adequate myocardial function. Increased sphericity. The LV wall thicknesses are irregular with regions of thinning. There is a diffusely hyperechoic endocardium consistent with mild fibrosis. The papillary muscles are mildly remodeled and hyperechoic.

Left atrium: The left atrium is normal in dimension. No obvious spontaneous contrast or thrombi seen.

AGE

8 years

Mitral valve: The mitral valve is thickened with abnormal closure. No mitral regurgitation.

Aortic valve/aorta: The aortic valve is normal in morphology and mobility. Normal aortic outflow velocity; laminar flow. No aortic insufficiency.

Right ventricle: Normal right ventricular diameter and morphology indicating no overt evidence of pulmonary arterial hypertension.

Right atrium: The right atrium is normal in dimension.

Tricuspid valve: The tricuspid valve appears normal with no tricuspid regurgitation.

Pulmonic valve/pulmonary artery: The pulmonic valve is normal in morphology and mobility. No pulmonic insufficiency. Normal RVOT velocity; laminar flow.

Pericardium/other: No pericardial or pleural effusion noted. No obvious cardiac masses.

WEIGHT

11.3lbs

INTERPRETED BY

Maggie Machen
Lamy, DVM
DACVIM (Cardiology)

IMAGING

PERFORMED BY

Pamela Harrigan,
RDCS

HOSPITAL NAME

Mendon Animal Clinic

2-Dimensional Measurements

Ao diam (cm)	1.0
LA diam (cm)	1.3
LA:Ao (Swe)	1.3
IVS thickness (cm)	0.43
LVID diastole (cm)	1.4
PW thickness (cm)	0.46
LVID systole (cm)	0.8
FS (%)	42

Doppler Measurements

PV Vmax (m/s)	0.8
AoV Vmax (m/s)	1.1
MR Vmax (m/s)	NA
TR Vmax (m/s)	NA
TR PG (mmHg)	NA

REFERRING VET

Dr. Cervasio

INTERPRETATION OF THE FINDINGS

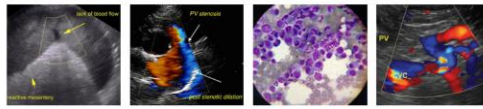
The primary abnormality identified is a highly remodeled LV with regions of thinning. This may be a normal variant; however, there is concern for early restrictive disease (RCM). The LA is normal indicating low risk for complication at this time. No additional issues are identified.

INVOICE

30229

DATE

4/13/23



PATIENT

Morrison Sgrosso

SPECIES

Feline

BREED

DSH

SEX

Male Neutered

AGE

8 years

WEIGHT

11.3lbs

INTERPRETED BY

Maggie Machen
 Lamy, DVM
 DACVIM (Cardiology)

IMAGING PERFORMED BY

Pamela Harrigan,
 RDCS

HOSPITAL NAME

Mendon Animal Clinic

REFERRING VET

Dr. Cervasio

INVOICE

30229

DATE

4/13/23

The ECG does confirm isolated and couplet ventricular premature contractions (VPCs). VPCs can certainly be cardiac in origin with significant structural disease; however, that is not clearly identified here. Extra-cardiac causes should be considered, including systemic disease, neoplasia, etc. Full systemic work-up is advised if not recently performed. The finding of tight couplets is concerning for malignant arrhythmias and Atenolol is recommended as below. Close monitoring for any associated clinical signs including collapse or significant lethargy is advised with immediate re-evaluation in these instances. Prognosis is guarded, as in any arrhythmic patient sudden death is certainly a possibility even on medications.

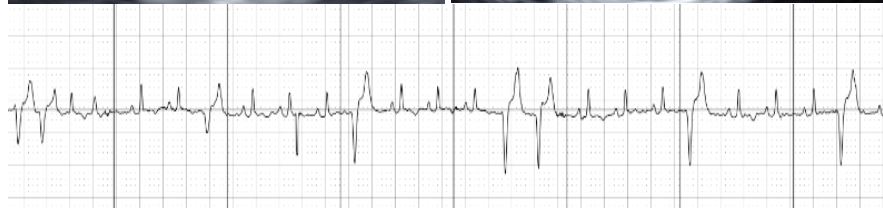
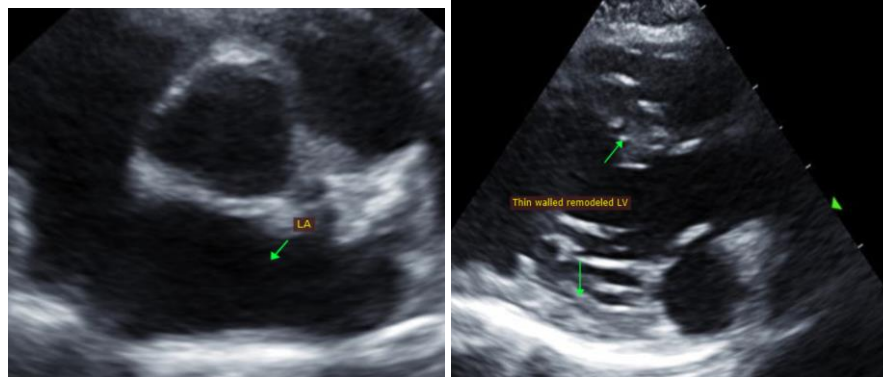
RECOMMENDATIONS

- Institute Atenolol 6.25mg PO q24h.
- Reassess ECG in 1-2 weeks. If couplets persist, increase to q12h dosing. If persistent despite BID dosing, consider submit ECG for reevaluation.
- Full systemic evaluation is advised.
- Elective anesthesia is not advised prior to further systemic evaluation and monitoring.
- Monitor for any signs of sustained arrhythmias including collapse or significant lethargy.
- Monitor for any change in breathing rate or effort, or signs of a blood clot event.

PLAN

- Recheck echocardiogram and ECG are recommended in 6 months to assess for any abnormalities not identified on this exam.

IMAGES





PATIENT

Morrison Sgrosso

The information and recommendations provided are based on the images presented by the referring veterinarian. No evaluation can be communicated regarding pathology that was not visible in the image/video clips provided.

SPECIES

Feline

Thank you for this referral. This report was generated using transcription software, and minor dictation errors may be present. If the clinical or image interpretation does not parallel your findings or if I can be of any further assistance, please contact me.

BREED

DSH

Maggie Machen Lamy, DVM
Diplomate of the American College of Veterinary Internal Medicine (Cardiology)
info@sonopath.com

SEX

Male Neutered

Echocardiogram performed by: Pamela Harrigan, RDCS
Pet Animal Ultrasound Service (4paus.com)

AGE

8 years

WEIGHT

11.3lbs

INTERPRETED BY

Maggie Machen
Lamy, DVM
DACVIM (Cardiology)

**IMAGING
PERFORMED BY**

Pamela Harrigan,
RDCS

HOSPITAL NAME

Mendon Animal Clinic

REFERRING VET

Dr. Cervasio

INVOICE

30229

DATE

4/13/23